

Colic, Colonic Ulcers and the Equine Digestive Tract

Necroscopic analysis of ulcerated horses, combined with other existing data, may provide a lead into the underlying etiology of many idiopathic colics.

A paper presented by:
Freedom Health, LLC

Last revision:
August, 2011

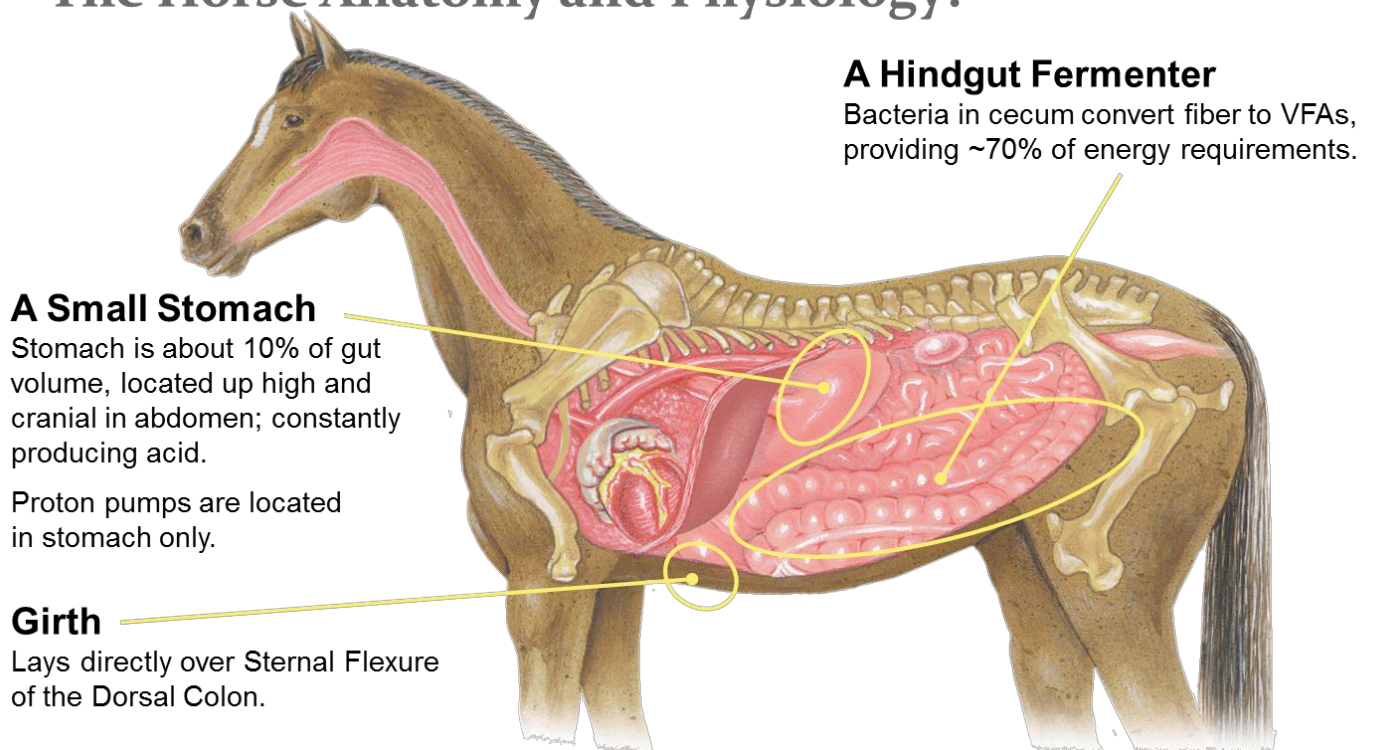
INTRODUCTION

Many studies exist that show gastric ulcers are present in horses that colic, and articles continue to be published suggesting that gastric ulcers are causative. In fact, no evidence exists whatsoever to prove causation in most instances: perhaps, because gastric ulcers are often also present when colonic ulcers exist, some have erroneously concluded that gastric ulcers are causative when they simply correlate. Meanwhile, the vast majority of colics are idiopathic.

This paper presents the peer-reviewed supportive science linking colonic ulceration with colic. It also discusses symptoms that may provide advanced warning of an impending colic, thus allowing you to take the appropriate avoiding action.

The following schematic will help when reviewing this paper:

The Horse Anatomy and Physiology:



THE SCIENCE

1. Background

Horses are hind gut fermenters. Naturally, they are grazing herbivores, intended to graze 18+ hours in every 24. Their digestive systems have evolved accordingly:

- Constant chewing, producing alkaline saliva which buffers gastric acid.
- A low-capacity stomach, with continual secretion of hydrochloric acid. Food passes through the stomach swiftly (< 1 hour.)
- A small intestine, approximately 70' in length, where vitamins, fats and oils, and simple sugars are absorbed. Again, there is a rapid transit time of about 1' per minute.
- The majority of nutrient/energy uptake occurs as a result of bacterial fermentation of structural carbohydrates into Volatile Fatty Acids in the cecum and colon.

The horse would normally produce about five gallons of saliva every day, and eventually “recycle” much of the water content via re-absorption prior to excretion.

In recent times, especially the past 50 years, equine husbandry has changed dramatically and, for the most part, has become detrimental to the horse. This is due, in part, to lack of awareness, since many of those involved in the care of horse have had little handed down to them from knowledgeable horse people of the past. It also has to do with a combination of the modern human lifestyle (time-constraints), a loss of good pasture (suburbanization), and the marketing of feeds, supplements and drugs which can provide significant misinformation to practitioner and lay person alike.

As a result, today's horse is often fed intermittently, with a high proportion of concentrates in its diet, and is often stall-bound and isolated for much of its time, usually without hay (forage) to chew on.

The behavioral and symptomatic effects are obvious to all, yet are often misunderstood.

2. The Impact of Grain on the GI Tract

Pellegrini's paper on the incidence of gastric and colonic ulceration in performance horses, published in 2005, shows ulcer incidences of 88% gastric and 63% colonic among performance horsesⁱ. Most horses with colonic ulcers also suffered from gastric ulceration. Multiple studies over time (on cohorts of all types of horses) have revealed the following:

	2003	2007	2008	2009
N	365	86	111	188
Gastric	55%	60%	43%	48%
Colonic	44%	87%	85%	74%

While these results may appear surprising, the science that leads to this is well documented in peer-reviewed papers. Until Pellegrini's work, the pieces of this jig-saw puzzle did not come together. The etiology of most idiopathic colic now appears to have a logical foundation:

- It is well-understood and documented that grain reaching the hind-gut of the horse causes the simple carbohydrates (starches and sugars) to be fermented into lactic acid, lowering the pH.
- Julliand et al. (2001) showed that even the smallest quantities of grain will reduce the pH, and lowering of pH is accelerated as grain intakes risesⁱⁱ.
- As the pH falls, especially below 6.5, beneficial VFA production reduces while a simultaneous bacterial "inversion" takes place: beneficial, forage-fermenting bacteria die off to be replaced by ever increasing proportions of pathogenic bacteria (e.g. lactobacillus)ⁱⁱⁱ.
- Clarke et al. (1990) showed that, along with reduced pH and an accumulation of lactic acid, endotoxins are released^{iv}.
- Weiss et al. (2000) have shown that in vitro exposure of colonic mucosa to cecal contents incubated with starch resulted in increased paracellular permeability^v.
- Studies by Oikawa et al. (2002 - 6) have shown mesenteric arterionecrosis occurs and can be induced via endotoxemia, and that colic symptoms can be induced via injecting the anterior mesenteric artery with these endotoxins. Further, they have shown these mesenteric arteriolar lesions "consisted of a striking loss of medial smooth muscle cells."^{vi, vii, viii}

The etiology of colonic ulceration is not yet understood. However, our own analysis and observations of colonic tissue in hundreds of necropsies, over the course of four separate studies in six years, lead us to believe it may involve the action of pathogenic bacteria on the exposed, compromised mucosal lining. Regardless, the widespread existence of colonic ulcers cannot be denied, nor the subsequent results of endotoxins or exotoxins entering the bloodstream.

COLONIC ULCERS AND COLIC

In the real world, it is likely that the aforesaid reactions take place over an extended period. Horses exhibiting abdominal discomfort may be in the initial stages of this process, perhaps irritated from hind-gut acidosis, or perhaps from developing ulcerative lesions

Whenever blood flow is diminished, the first effects are seen at the end of the corresponding arterial network. Thus, when blood loss from ulceration results in the constriction of mesenterial arteries, the effects may include a necrosis of tissue in the portion of the digestive tract fed by these arteries, such as the pelvic flexure or the last few feet of the ilium. If this occurs, it would likely result in diminished peristalsis at that same location. This may explain incidents of intermittent impaction colics.

At the opposite extreme, when colic surgery is required, the historical approach was resection. Due to the poor prognosis, this procedure has now largely ceased. We suggest the poor prognosis is due to significant colonic ulceration, resulting arterionecrosis and, thus, the almost certain reoccurrence due to loss of blood flow.

In the course of Pellegrini's unpublished necropsy work, horses with colonic ulcers were generally observed to have flaccid colons, while non-ulcerated horses have a plump, healthy organ. In extreme circumstances, with extensive ulceration, the colon wall collapses to resemble a sausage skin. These observations appear to be corroborated by Oikawa's findings.

Based on these observations, we believe that many torsion colics can now be better explained. A flaccid organ may not be as effectively held in place by the mesentery as a healthy colon, allowing this to occur.

DIFFERENTIATING SYMPTOMS OF COLONIC & GASTRIC ULCERATION

Unfortunately, some textbooks and articles continue to misinform, and attribute the symptoms of (perhaps hind-gut acidosis and) colonic ulcers to gastric ulceration. This is perhaps because gastric ulcers are often present simultaneously with colonic ulcers, while a colonoscopy is not practical with a live horse, leading to the erroneous conclusion of causation.

It is vital that the practitioner can separate gastric from colonic ulceration. While endoscopy can be valuable, certain non-invasive techniques may help.

Colonic Ulcer Symptoms

In the last several years, a number of visible signs have been attributed to gastric ulcers. Some of these symptoms do not logically stem from gastric injury, but are more likely associated with colonic ulceration. Evaluating various symptoms in conjunction with our own observations of horses produces the following set of proposed symptoms of colonic ulcers:

Girthiness – can only be hind-gut ulceration. The girth squeezes on the cranial portion of the dorsal colon.

Sensitivity along the flanks, especially the right side since the cecum empties into the right ventral colon.

“Tucked-up” abdomens: a signal that the colon has diminished in size, likely shriveled.

Poor hair-coat and eye: signals that nutrient uptake is less than optimum, suggesting the hind-gut may not be working effectively.

Diarrhea: intermittent or regular. Diarrhea is mostly a signal that the hind-gut is not working correctly: occasionally, small intestinal diarrhea may occur.

Fecal pH is 6.5 or less. The optimum pH for feces is 6.85, while practical experience indicates it ranges throughout the day (with horses fed grain or concentrates) between about 6.7 and 6.9. A food-probe pH meter will provide results in seconds.

Difficulty bending or collecting, especially fully collecting the right hind.

Any and all of these may be indications of colonic ulceration and may aid a practitioner’s diagnosis.

Additionally, the practitioner may use CBC analysis to aid in diagnosis of colonic ulceration. Often, low albumin levels are seen, with no obvious cause, and are diagnosed as “Protein Losing Enteropathies.” Albumin is the first blood component to be exuded when ulcers or lesions form. Thus, a protein losing enteropathy may have actually be a result of colonic ulceration (since gastric ulceration is usually of such a small surface area that insufficient albumin loss will occur to induce this reading on a CBC).

This condition can be further evaluated with a commercially available antibody test called the SUCCEED® Equine Fecal Blood Test™ [“FBT”]. The FBT measures excess Albumin and Hemoglobin (i.e. above defined levels) in an equine fecal sample. Since Albumin is destroyed by enzymatic activity around the common bile duct, it can be used as a marker for hind gut lesions. Hemoglobin is only present when Grade 2 or higher (ulcer equivalent) lesions occur.

If action is not taken to restore digestive integrity, colic may eventually ensue.

Gastric Ulcer Symptoms

Certain stereotypies have been associated with gastric ulceration:

Cribbing (wind-sucking) has been shown to be a signal of gastric ulceration. Likely, the horse has learned to expand its stomach volume, thereby reducing the acid level in the stomach and relieving the discomfort.

Wood-chewing has also been associated with gastric ulcers. Likely, the horse has little forage available to it and has learned that chewing wood will cause salivation and some relief, even if the ingesta provides no nutritional value.^{ix}

Additionally, since gastric and colonic ulcers often occur together, symptoms of colonic ulceration may also be associated with gastric ulcers and the direct causation may be difficult to isolate:

- Intermittent colic
- Difficulty maintaining weight
- Bruxism
- Poor performance
- Drab coat
- Poor eye

One simple technique to help provide a preliminary indication of whether gastric ulcers are present involves the reaction of the horse to drinking water at different temperatures. Pellegrini found that if an adverse reaction (signs of discomfort) is reported in response to the ingestion of cold drinking water, in conjunction with an enthusiastic response to warm drinking water, gastric ulcers can be strongly suspected.

If these symptoms, perhaps confirmed with endoscopy, cause the practitioner to prescribe/use a gastric acid inhibitor, then grain and concentrates should be removed from the animal’s diet until treatment ceases, unless further action is taken to preserve the integrity of the hind-gut. It needs to be remembered that low stomach pH has a purpose:

- A. Low pH in the stomach may prevent multiplication of ingested bacteria (except lactobacilli).

- B. Digestive enzymes have a fairly narrow range of optimum pH: change decreases the rate of hydrolysis or activity at either side of the peak.^x
- C. Gastric HCl in the duodenum stimulates release of the polypeptide hormone secretin into the blood. The horse lacks a gall bladder, but stimulation of bile is also caused by the presence of gastric HCl in the duodenum.^{xi}

If the animal exhibits symptoms of colonic ulceration, it is even more vital that various avoidance mechanisms are used to avert more serious conditions (such as colic) emerging.

DISCUSSION

It will, by now, be clear to the veterinarian that both gastric and colonic ulcers in equines are better described as induced conditions rather than diseased states. The well-known “cure” is simply to turn a horse out to pasture for a few months. If the condition is reversible by simply allowing the animal to feed and digest naturally, it is equally clear that GI tract ulceration is an induced condition arising from modern husbandry.

Ideally, we would revert to feeding practices of 100 years ago. Unfortunately, this is not practical or economical for most. Thus, we are forced to alternatives that will allow the horse to digest as close to natural as possible, and minimize the side-effects of modern feeding regimens. Such a solution would:

- Minimize the amount of grain (simple carbohydrates) reaching the hind-gut, through both slowing down the passage of grains and enhancing nutrient uptake, thus reducing the total amount of grain required to maintain body weight and athletic performance.
- Provide the nutrients to strengthen and preserve the integrity of the gut wall (both stomach and hind-gut).
- Help normalize the digestive flora, eliminating an excess of pathogenic bacteria and endotoxins.
- Enhance the immune system for self-repair.

In order to maximize the client’s success with their horse and to minimize the risks of colic, it is vital that the practitioner is aware of the stereotypies involved, can ask appropriate questions during examination, and develop a proper differential diagnosis. Given that most colics are currently idiopathic, we hope this material will allow a more positive outcome, even possible elimination of most colics through early diagnosis of the symptoms and likely causes that lead to these conditions.

-
- ⁱ Pellegrini FL, Results of a large-scale necroscopic study of equine colonic ulcers, *J Equine Vet Sci*, 2005; 25(3):113-117.
- ⁱⁱ Julliand V. et al. Feeding and microbial disorders in horses: Part 3—Effects of three hay:grain ratios on microbial profile and activities, *J Equine Vet Sci*. 2001, 21(11), 543-546.
- ⁱⁱⁱ Swyers KL et al. Effects of direct-fed microbial supplementation on digestibility and fermentation end-products in horses fed low- and high-starch concentrates, *J Anim Sci*. 2008. 86:2596-2608.
- ^{iv} Clarke LL et al. Feeding and digestive problems in horses: physiologic responses to a concentrated meal. *Vet Clin North Am Equine Pract*. 1990, 43(8), 433-450.
- ^v Weiss DJ et al. In vitro evaluation of intraluminal factors that may alter intestinal permeability in ponies with carbohydrate-induced laminitis, *Am J Vet Res*, 2000, 61(8), 858-861.
- ^{vi} Oikawa et al. Equine endotoxemia: pathomorphological aspects of endotoxin-induced damage in equine mesenteric arteries, *J Vet Med, A-49*, 2002, 173 -176.
- ^{vii} Oikawa et al. Arterionecrosis of the equine mesentery in naturally occurring endotoxemia. *J Comp Path* 2004, Vol 130, 75 – 79.
- ^{viii} Oikawa et al. Mesenteric arterionecrosis in natural and experimental equine endotoxemia. *J Comp Path* 2006, Vol 134, 47 – 55.
- ^{ix} Nicol C. Understanding equine stereotypies. *Equine Vet J*, Vol. 31, S28, 1999, 20-25.
- ^x Chiba LI, Digestive Physiology, *Animal Nutrition Handbook*, Auburn University, 2009.
- ^{xi} Frape D, *Equine Nutrition and Feeding, 4th ed.* London, Wiley-Blackwell, 2010.